D2.0 ENT

Ear and nose
The history may be obvious or the child may present with a unilateral foul discharge. Removal requires co-operation of the child appropriate instrument .
Never pursue a FB in an uncooperative child with poor instruments and lighting.
Vegetable matter requires more urgent removal due to the fact there is a large inflammatory response to this

2.1 Bell's Palsy

- This is acute seventh nerve paralysis. Make sure you differentiate upper and lower motor neurone problems.
- It may be associated with postauricular pain, tinnitus or hearing loss. Look for vesicles in the external auditory meatus. If so treat as shingles
- A significant number (>50%) resolve completely. Present management involves a short course of oral steroids 40-60mg od of prednisolone, and ENT outpatients at 1 week. Also consider prophylactic acyclovir.
- If the eye does not close on blinking do not tape the eye closed as keratitis is unusual. If present discuss with Ophthalmology. Treatment will be artificial tears.

2.2 Earache
Ear ache can be due to problems in the ear or referred from such sites as teeth, T-M joint, pharynx, c spine etc

Otitis externa

- This is common after minor trauma. An itch ear is proceeded by increasing pain and a discharge
- On examination the external canal is oedematous and inflamed which together with debris may obscure the Tympanic membrane
- Pressing on the tragus or pulling the ear causes pain.
- Treatment involves topic antibiotics +/- steroids topically. If there is a profuse debris this will need to be cleaned and referral to the ENT clinic should be arranged.

Otitis media

- Most common in children following URTI
- Commonest cause is viral, Strep pneumonia and H Influenza.
- Earache may be accompanied by deafness , irritability, fever
- The TM is inflamed on examination and is bulging with loss of light reflex
- Perforation leads to discharge and relief of pain
- Beware of secondary mastoiditis
- Treatment is with analgesia and oral antibiotics (little evidence for its value)

Acute mastoiditis

- This is rare but should not be missed as there is risk of intarcranial spread
- Commonly follows otitis media
- The mastoid appears red , hot and swollen with increasing pain.
- Refer urgently to ENT

Cholesteatoma

- This is an erosive condition affects the middle ear and can be very destructive leading to intra-cranial spread
- There may be a discharge with hearing loss and vertigo and facial nerve palsy
- The TM appears to have granulation tissue over it
- Refer to ENT

2.3 Ear injury

- First establish whether the injury is external or beyond what you can see. If the latter, or if hearing is affected, the patient should be referred to ENT, either immediately, or to the next clinic.
- If external, repair the wound carefully, and pack over the pinna with cotton wool if appropriate.
- Foreign bodies should only be removed if superficial; a lot of damage can result from deep/blind probing.
- Early "cauliflower ear" can be treated by aspiration of the haematoma, and pressure bandaging over the ear, having carefully applied cotton wool to the pinna to maintain the normal contours.

2.4 Epistaxis

See flow chart.

- Distinguish between the simple epistaxis in the under 50 year old, non hypertensive, non anti-coagulated patient, and the potentially complicated epistaxis in a patient who is either over 50 years old**,** hypertensive or anti-coagulated.
- Simple epistaxis can usually be treated with pressure, or silver nitrate cautery.
- Patients with complicated epistaxis should have pulse, BP, FBC, clotting, G&S and IV access, then examination with Brompton's Cocaine.
- Anterior bleeding can be cauterised with silver nitrate**,** but otherwise a nasal tampon should be inserted.

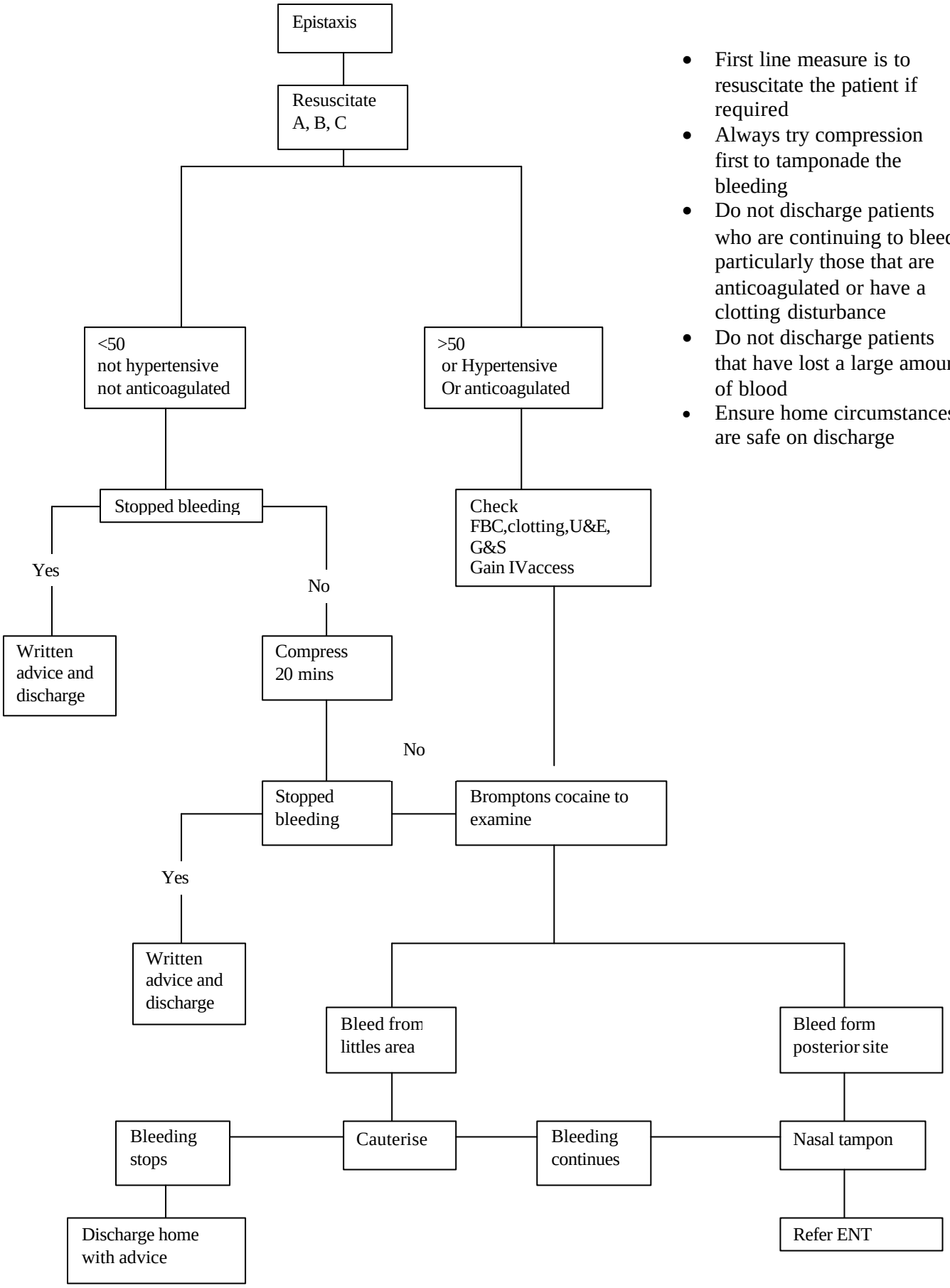

- First line measure is to resuscitate the patient if required
- Always try compression first to tamponade the bleeding
- Do not discharge patients who are continuing to bleed particularly those that are anticoagulated or have a clotting disturbance
- Do not discharge patients that have lost a large amount of blood
- Ensure home circumstances are safe on discharge